



Attorney Docket No.: SD1140-

1614
RECEIVED
APR 11 2003
TECH CENTER 1600026000

IN THE UNITED STATES PATENT AND TRADEMARK OFFICE

Applicant: Robert K. Naviaux Art Unit: 1614
Application No.: 09/889,251 Examiner: P. Spivack
Filed: November 1, 2001
Title: METHODS OF TREATMENT OF MITOCHONDRIAL DISORDERS

Commissioner for Patents
Washington, DC 20231

TRANSMITTAL SHEET

Transmitted herewith for the above-identified application, please find:

- (1) Replacement Declaration of Applicant Under 37 C.F.R. §1.132 (8 pgs); and
- (2) Return Receipt Postcard.

CERTIFICATION UNDER 37 CFR §1.8

I hereby certify that the documents referred to as enclosed herein are being deposited with the United States Postal Service as first class mail on April 11, 2003, in an envelope addressed to: Commissioner for Patents, Washington, D.C. 20231

Cara Grifone 4-11-03
Cara Grifone

In the Application of
Robert K. Naviaux
Application Serial No.: 09/889,251
Filed: November 1, 2001
Page 2

PATENT
Attorney Docket No.: UCSD1140-1

Enclosed herein is a substitute Declaration under §1.132 following an initial submission on April 3, 2003. Please substitute this Declaration for the one submitted with the Response on April 3, 2003 and please do not enter the prior Declaration. No fee is believed due in connection with the filing of this document. In the event that a fee is due, the Commissioner is hereby authorized to charge any other fees that may be associated with this communication, or credit any overpayment to Deposit Account No. 50-1355.

Respectfully submitted,

Date: April 11, 2003




Lisa A. Haile, J.D., Ph.D.
Registration No.: 38,347
Telephone: (858) 677-1456
Facsimile: (858) 677-1465

USPTO CUSTOMER NUMBER 28213
GRAY CARY WARE & FREIDENRICH LLP
4365 Executive Drive, Suite 1100
San Diego, CA 92121-2133

Application No.: 09/889,251
Applicant: Robert K. Naviaux
Filed: November 1, 2001

PATENT
Attorney Docket No.: UCSD1140-1



Page 1

IN THE UNITED STATES PATENT AND TRADEMARK OFFICE

Applicants: Robert K. Naviaux Art Unit: 1614
Application No.: 09/889,251 Examiner: P. Spivack
Filed: November 1, 2001
Title: METHODS OF TREATMENT OF MITOCHONDRIAL DISORDERS

RECEIVED
APR 17 2003
TECH CENTER 1600/2800

Commissioner of Patents
Washington, D.C. 20231

DECLARATION OF
APPLICANT UNDER 37 C.F.R. § 1.132

Sir:

I, Robert K. Naviaux, inventor of the above-identified application, do hereby declare and state that:

1. I am familiar with the above-identified patent application and the disclosure in the Specification of methods for treating various disorders.
2. I have reviewed the Office Action mailed December 18, 2002, and I understand that claims 1-28 and 66 have been rejected, *inter alia*, under 35 U.S.C. § 112, first paragraph, for allegedly lacking enablement. I further understand that the Examiner has alleged that the breadth of the claims with respect to treating all mitochondrial disorders is extremely broad, and that allegedly little is known about the etiology and the pathophysiology of the various disorders set forth in dependent claim 7 and generally encompassed in independent claims 1, 2, 25, and 26.
3. I have demonstrated, using the methods disclosed in the above-identified application, that pyrimidine therapy can be used to effectively treat various disorders. In addition, I have found that conditions set forth in the claimed invention can be effectively treated by administration of pyrimidine-based nucleosides.
4. As set forth in the Exhibit accompanying this Declaration, various disorders can be effectively treated by administering triacetyluridine (TAU) to subjects in need thereof.

Gray Cary/GF16338102.3
101649 17

Application No.: 09/889,251
Applicant: Robert K. Naviaux
Filed: November 1, 2001
Page 2

PATENT
Attorney Docket No.: UCSD1140-1

Specific disorders that can be effectively treated using the methods of the invention include renal tubular acidosis (RTA); Leigh syndrome; MARIAHS syndrome; mitochondrial disease leading to stroke-like episodes; lactic acidemia; seizure disorders associated with mitochondrial dysfunction; migraine headaches associated with mitochondrial dysfunction; painful polyneuropathy associated with mitochondrial dysfunction; Pyruvate Dehydrogenase (PDH) deficiency; encephalomyopathy; ataxia and encephalopathy; cytochrome c oxidase (COX, Complex IV) deficiency; cardiomyopathy; Alzheimer's disease; Complex I deficiency; multiple mitochondrial deletion syndrome, and any combination thereof. The accompanying Exhibit sets forth experimental protocols and results obtained in support of this statement.

5. I further declare that all statements made herein of knowledge are true and that all statements made on information and belief are believed to be true, and further that these statements were made with the knowledge that willful false statements and the like so made are punishable by fine, or imprisonment, or both under Section 1001 of Title 18 of the United States Code, and that such willful false statements may jeopardize the validity of the application or any patent issued thereon.

4-10-03
Date

R K Naviaux
Robert K. Naviaux

Attachment: Exhibit A To Declaration

PYRIMIDINE THERAPY OF MITOCHONDRIAL DISEASE—

EXAMPLES

Example 5. Treatment by administration of triacetyluridine to a subject with cytochrome c oxidase deficiency. Leigh Syndrome, and renal tubular acidosis.

Patient. KD is a 3 year old girl with Leigh syndrome, lactic acidemia, and renal tubular acidosis secondary to cytochrome c oxidase (COX, Complex IV) deficiency, and iron deficiency anemia despite regular iron supplementation in her multivitamins. She required 200 mEq/day of sodium bicarbonate (16 mEq/kg/d) to compensate for renal tubular losses and had frequent episodes of metabolic acidosis and volume depletion from unchecked urinary alkali and fluid losses.

Treatment. TAU therapy was begun and maintained at 2 g/m² per mouth three times a day.

Results. Upon enrollment in the TAU study her serum bicarbonate was 20 and urinary bicarbonate was 99 mEq/l. Her fractional excretion of bicarbonate (FE_{HCO₃}) was 9.3% prior to therapy. After 36 hours on treatment with TAU, the FE_{HCO₃} fell to less than 0.4%, and her urinary bicarbonate losses were undetectable (<5 mEq/l). She now requires just 4 mEq/kg/d of sodium bicarbonate to maintain her serum bicarbonate > 20. After 6 weeks on TAU, her gait and strength are improving. Fine motor ataxia is much reduced, enabling her to use a precise pincer grasp. For the first time she is able to walk, stop, and pick up objects from the floor while standing. In the first year of therapy, she had no hospitalizations, her appetite has increased dramatically, and she has maintained a blood bicarbonate of 20 with just 50 mEq/d of oral sodium bicarbonate. She has done well for over 2 1/2 years of therapy. Her iron deficiency anemia has disappeared, she is gaining milestones, talking in 3-6 word sentences, able to laugh and play with her younger, unaffected sister. TAU therapy was associated with initial stasis, then much reduced progression of her Leigh syndrome, which had caused aggressively progressive neurodegeneration prior to therapy.

Example 6. Treatment by administration of triacetyluridine to a subject with cytochrome c oxidase (COX, Complex IV) deficiency, Leigh Syndrome, lactic acidemia, optic atrophy, ataxia, frequent upper respiratory tract infections,

Patient. CB is a 6 year old boy with Leigh syndrome and cytochrome c oxidase deficiency who was diagnosed and begun on treatment for lactic acidemia with sodium dichloroacetate (DCA) since age 3. Despite DCA therapy, he continued to have frequent upper respiratory tract infections that were associated with loss of motor tone, inability to sit unassisted, and many school day absences. These episodes occurred 6-10 times per year prior to TAU therapy. In addition, the patient suffered from frequent (8-10 per month) migraine headaches, and painful peripheral polyneuropathy in his hands that was not responsive to thiamine and other B-vitamin therapy. He also suffered with truncal ataxia, titubation, dysarthria, and lower extremity spasticity that required him to use a custom wheel chair for most of the day.

Treatment. TAU therapy was begun and maintained at 2 g/m² per mouth or by gastrostomy tube three times a day.

Results. In the first month of TAU therapy, appetite and hand coordination were improved. He had only 3 headaches, which disappeared after the first month of treatment. After two months, his painful polyneuropathy was gone. After three months, he was noted to have significantly improved hand and truncal coordination, improved head control, reduced titubation, and reduced upper extremity ataxia. Prior to TAU therapy he had 5-7 respiratory tract infections requiring treatment every year and several days off from school. After TAU therapy, he has 2-3 infections per year. None of these have required hospitalization, and the number of days off from school is much reduced. He has learned to read and type. He continues to have a good therapeutic response to TAU therapy after 3 years, and is performing at grade level in the 4th grade with the assistance of a large-letter computer screen and keyboard to assist him because of his poor vision associated with optic atrophy. He is cheerful and optimistic, and enjoys telling jokes to friends and his physicians. The optic atrophy did not improve with TAU therapy.

Example 7. Treatment by administration of triacetyluridine to a subject with Pyruvate Dehydrogenase (PDH) deficiency, encephalomyopathy, Leigh Syndrome, and developmental delay.

Patient. KJ is a 2 year old boy with Leigh syndrome, lactic acidemia, and renal tubular acidosis secondary to pyruvate dehydrogenase (PDH) deficiency. He required up to 210 mEq/day of sodium bicarbonate (18 mEq/kg/d) to compensate for renal tubular losses. His blood lactic acid ranged from 4-8 mM. Prior to treatment with TAU, this patient had 4-6 emergency room visits and hospitalizations per year for metabolic acidosis and volume depletion, often associated with mild childhood infections, and severe psychomotor developmental delay.

Treatment. TAU therapy was begun and maintained at 2 g/m² per mouth or gastrostomy tube three times a day.

Results. Upon enrollment in the TAU study his serum bicarbonate level was 16 mEq/l, and his urinary bicarbonate was 55 mEq/l. The fractional excretion of bicarbonate (FE_{HCO_3}) was 10.0% prior to therapy. After 36 hours of treatment with TAU, this fell to less than 0.4%, his serum bicarbonate was 19, and urinary losses were undetectable (<5 mEq/l). After 2 weeks of therapy, his serum bicarbonate was 24 on just 40 mEq/day of supplemental oral sodium bicarbonate. Moreover, his blood lactic acid had dropped from 6 to 2.2 mM with TAU therapy during the first month. Prior to starting TAU, his developmental age had arrested at the level of a 4-5 month old child (able to roll over once, but unable to pull to a sit) for the previous 10 months. After 6 weeks on TAU he was able to pull himself up to a sit, and began to use rolling as a means of locomotion on the living room floor to get closer to the TV. In the first year of therapy, he has had no hospitalizations, was experimenting with language, and is able to sit unassisted. In 4 years of therapy, KJ has had just one hospitalization, is learning to talk and feed himself.

Example 8. Treatment by administration of triacetyluridine to a subject with Complex I deficiency, Leigh Syndrome, cardiomyopathy, dysphagia, seizure disorder, dysautonomia, and involuntary movements.

Patient. MS is a 2 year old girl who was developmentally normal--walking and talking--until age 2, when she suffered a catastrophic neurodegenerative episode associated with an upper respiratory tract infection leading to shock and cardiorespiratory collapse. This episode left her unable to walk or talk. She was diagnosed with complex I deficiency and Leigh syndrome, dystonia, choreoathetosis, seizure disorder, apneic episodes, autonomic instability, cardiomyopathy, progressive encephalopathy, severe psychomotor delay, sleep apnea, frequent infections, proteinuria, frequent periods of agitation requiring ativan and chloralhydrate around the clock, dysphagia, oral secretion pooling requiring a G-tube for nutrition and hydration.

Treatment. TAU therapy was begun and maintained at 2 g/m^2 per gastrostomy tube three times a day.

Results. Within 4 days of initiating TAU therapy, there was marked reduction of her involuntary movements, which had previously included choreoathetosis of arms and legs, and lip and tongue automatism. After 2 weeks she was able to touch her head and nose on command. Within 2 weeks it was noted that her previous proteinuria had disappeared. Her swallowing and feeding by mouth was much improved, resulting in better oral secretion control and fewer episodes of aspiration, coughing, and respiratory infections. Seizure activity disappeared within 2 weeks of starting TAU and did not return for at least 4 months, as documented both clinically and by repeat EEG. Apneic episodes also vanished. Episodes of agitation were reduced, and she was able to nap more regularly during the day and rouse more playfully at night. Head control was improved, as she was able to hold her head up from a prone position for 12 seconds. She was unable to do this prior to TAU therapy because of a combination of involuntary movements and poor head motor control.

Example 9. Treatment by administration of triacetyluridine to a subject with NARP, a mitochondrial DNA disease that produced truncal ataxia, frequent falls, dysarthria, frequent migraine headaches

Patient. BF is a 10 year old girl with NARP (T8993C) whose brother had died with associated Leigh syndrome 4 years earlier. She has significant ataxia, gross and fine motor deficits, and mild dysarthria, but is able to read and write, performing at near grade level in school. In the 6 months prior to starting TAU she had experienced frequent migraine headaches, sometimes severe enough to prevent her from going to school. She had been participating in balance therapy in a horse-riding program for 3 months, but was unable mount the horse without assistance or to sit up while riding. She had to be strapped in while holding on to the horse's neck because of significant truncal ataxia.

Treatment. TAU therapy was begun and maintained at 2 g/m^2 by mouth three times a day.

Results. After one week of TAU therapy, her migraine headaches disappeared, and have not yet returned after 2 months. After 6 weeks, her strength and balance had improved so much that she was able to mount the horse unassisted and to ride sitting upright, without being strapped in, for the first time. Truncal ataxia was markedly reduced in 3 months of therapy, resulting in fewer falls, which were previously a constant source of embarrassment at school. Fine motor skills and handwriting were also improved. There was no effect during this 3 month trial on the patient's long-standing dysarthria.

Example 10. Treatment by administration of triacetyluridine to a subject with Alzheimer and Normal Pressure Hydrocephalus Dementia.

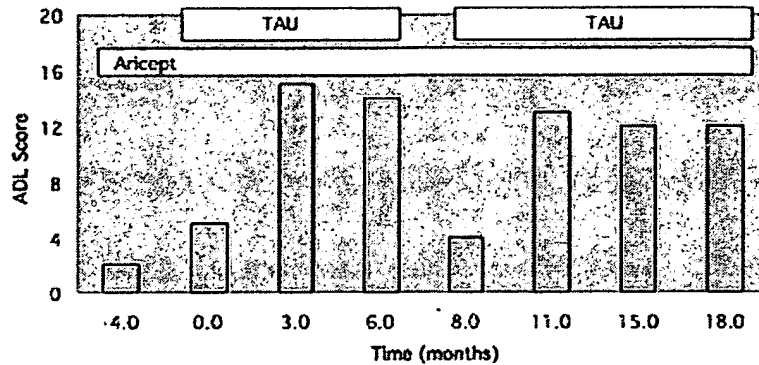
Patient. ME is an 84 year male with progressive dementia initially associated with normal pressure hydrocephalus. A ventricular-peritoneal (VP) shunt was placed with complete resolution of the hydrocephalus, but incomplete resolution of his dementia. Formal neurologic testing revealed underlying Alzheimer type dementia that was treated with Donepezil (Aricept).

Treatment. TAU therapy was begun and maintained at 2 g/m² per mouth three times a day, or 3 g/m² by mouth twice a day.

Results. Baseline Mini Mental Status Examination (MMSE) at age 84 showed a score of 18 out of 30. In addition to accelerating difficulties with cognitive performance, the patient was also experiencing significant depression, episodes of delirium, episodes of disorientation to place in his own home of 12 years, combative behavior, bowel incontinence, and deteriorating ability to perform routine activities of daily living (ADLs). He was started on Aricept (Donepezil) 4 months prior to therapy with TAU. Just before starting TAU, while continuing on Aricept, his MMSE score was 20, but he continued to suffer with significant depression, combative behavior, delirium, disorientation, incontinence, memory loss, and impaired performance of routine activities of daily living. Three months after starting TAU therapy, his ADL score rose from 4 to 15 (Fig. 1), his MMSE score rose from 20 to 26 (Fig. 2), and episodes of delirium and combative behavior were gone, disorientation was reduced, depression and incontinence were virtually eliminated, and short-term memory improved to the point that the patient could participate in family conversations again. This was associated with a dramatic reduction in his quantitative psychomotor disability score from 182 to 16 (Fig. 3). He returned to work in the garden and began playing the guitar again, which he had not done for 3 years. To establish the long-term need of TAU for maintenance of therapeutic effect, a 2 month, blinded drug holiday was initiated after 6 months of TAU therapy. Repeat MMSE exam was performed by a neurologist who was unaware of the TAU discontinuation. MMSE showed a dramatic deterioration from 24 to 19 (Fig. 2). In addition, his previous problems with delirium, disorientation, combative behavior, incontinence, depression, and ADLs reappeared. These promptly improved within a week of restarting TAU, and follow-up MMSE two months later showed a 4 point recovery in his score, which was 23. After 18 months of TAU his MMSE score is 22, his ADL score was stable at 12, and his psychomotor disability score was 19. A remarkably robust effect of TAU therapy has been its anti-depressant properties in this disease. Prior to treatment with TAU and during therapy with Aricept, ME was depressed and withdrawn. After TAU therapy his affect was bright and cheerful, giving him an excellent quality of life with his wife of 65 years. The

previous rate of progression of the patient's dementia, prior to TAU therapy, was reversed by therapy, then stabilized, and has shown only minimally detectable progression after more than 4 years of treatment with no significant side-effects other than stable swelling of the ankles.

Activity of Daily Living (ADL) Scores in a Patient with Alzheimer Dementia Treated with Triacetyluridine (TAU)



Activities of Daily Living (ADLs) included: 1) feeds self, 2) uses toilet unassisted, 3) shaves unassisted, 4) showers unassisted, 5) gets dressed unassisted, 6) washes dishes, 7) enjoys listening to music, 8) has a sense of humor--tells jokes, riddles, or puns, 9) takes a daily walk, 10) participates in group or family conversations, 11) makes fresh-squeezed orange juice and coffee unassisted, 12) gardening and weeding, 13) remembers to get the mail from the mailbox, 14) takes out the garbage, 15) plays piano or guitar, 16) works in the wood and metal shop.

Figure 1. Activities of Daily Living are Improved with TAU Treatment of Alzheimer Dementia, Fell During a Blinded Drug Holiday, and Recovered after Reintroduction of TAU Therapy.

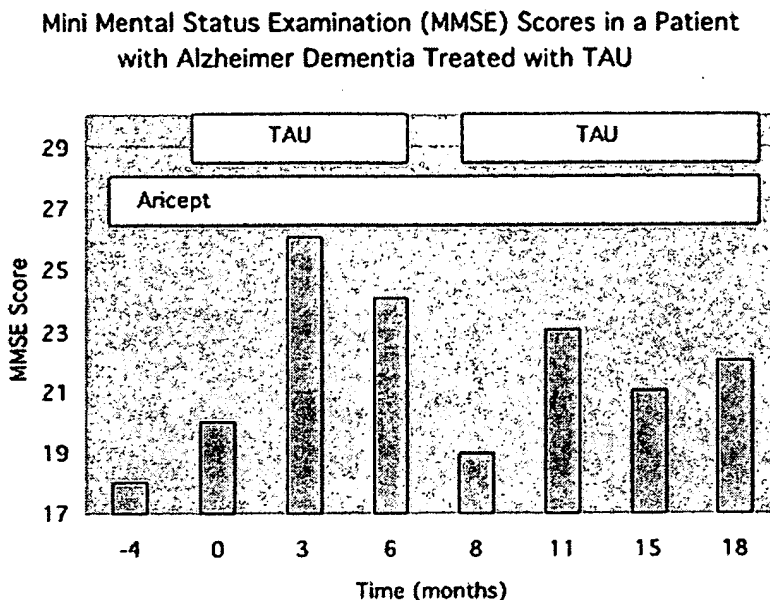


Figure 2. Mini Mental Status Examination Scores Improved with TAU Treatment, Fell During a Blinded Drug Holiday, and Recovered Upon Blinded Reintroduction of TAU Therapy.

Psychomotor Disability Scores in a Patient with Alzheimer Dementia Treated with Triacetyluridine (TAU)

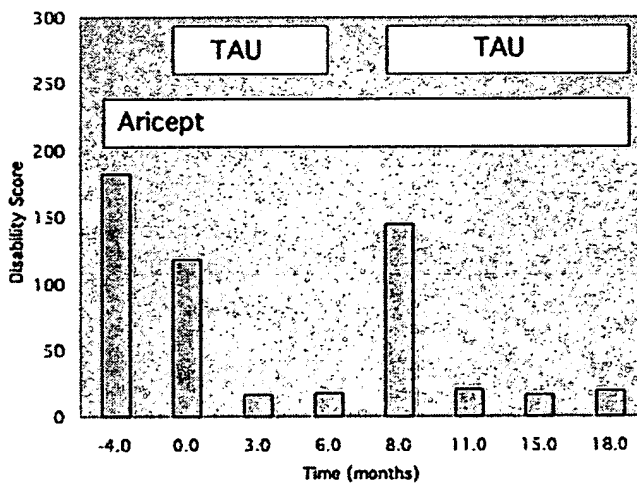


Figure 3. Psychomotor Disability from Alzheimer Dementia was Reduced by Therapy with TAU, Worsened During a Blinded Drug Holiday, and Recovered After Reintroduction of TAU Therapy.